

Sometimes It's PH

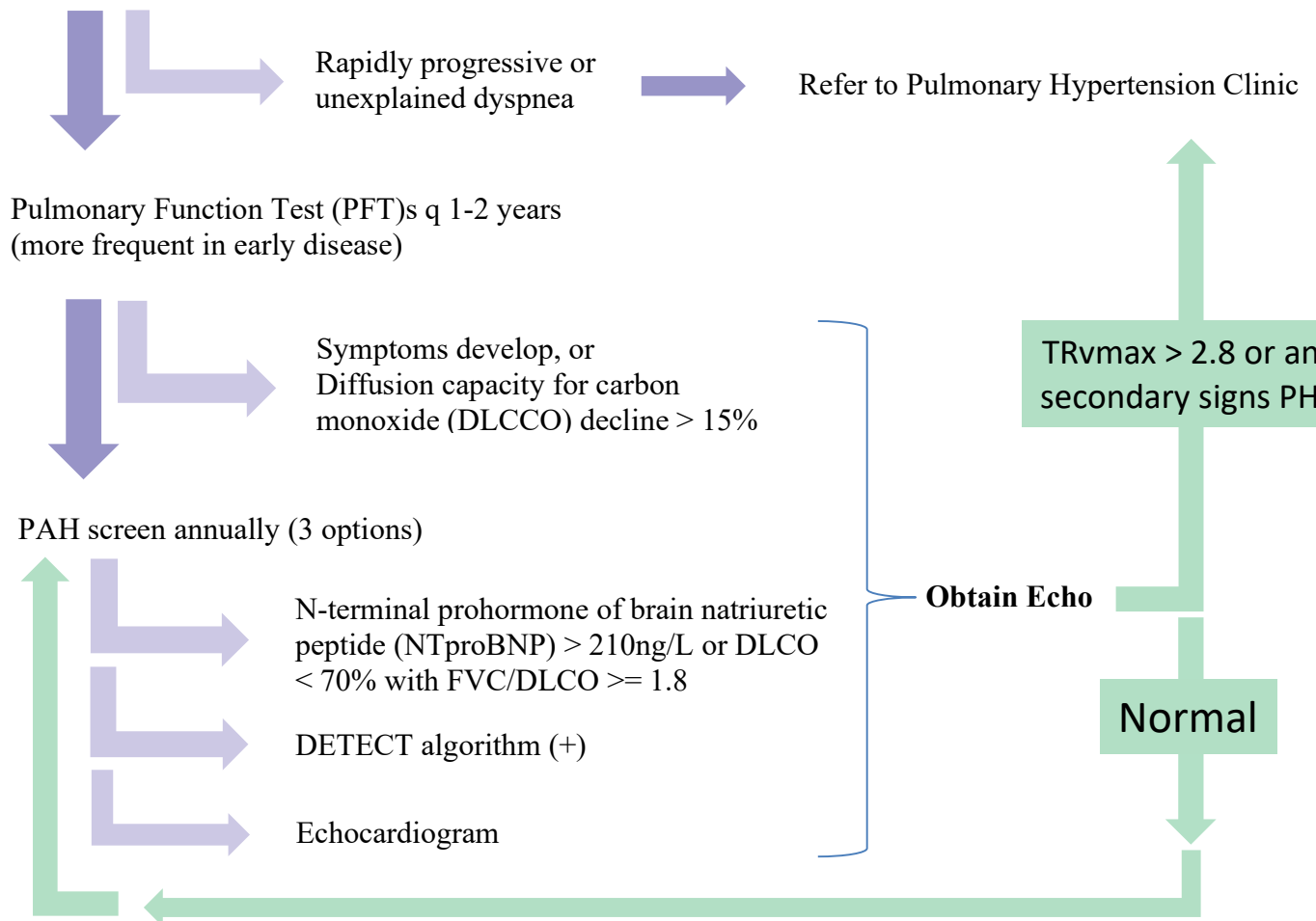
Sometimes what sounds like a horse... Could be a zebra.



Pulmonary hypertension is a medical zebra.

Screening for Pulmonary Arterial Hypertension in connective tissue disease

Scleroderma*



*Screening should also be considered for high-risk cases of SLE (low DLCO, RNP+) or overlap CTDs
DETECT algorithm available at: www.detectionofpah.com

** Secondary signs of PH on echo include RV or RA enlargement or dysfunction, pulmonary artery dilatation, interventricular septal flattening, or elevated estimated central venous pressure